

## **Novel 3D Computerized Threshold Amsler Grid Test**

*Wolfgang Fink<sup>1,2</sup> and Alfredo A. Sadun<sup>2</sup>*

<sup>1</sup>*California Institute of Technology, Pasadena, CA, USA*

<sup>2</sup>*Doheny Eye Institute, Keck School of Medicine, University of Southern California, Los Angeles, CA, USA*

First author and corresponding author:

Wolfgang Fink, Ph.D.

Visiting Associate in Physics at Caltech

Research Assistant Professor of Ophthalmology, Keck School of Medicine at USC

California Institute of Technology

Mail Code 106-38

Pasadena, CA 91125

Phone: (818) 393-2695

e-mail: wfink@krl.caltech.edu

Alfredo A. Sadun, M.D., Ph.D.

Professor of Neuro-ophthalmology and Neurosurgery at the Doheny Eye Institute

Keck School of Medicine at the University of Southern California, Los Angeles, CA, USA

Phone: (323) 442-6417

e-mail: asadun@usc.edu

## **Abstract**

**Purpose:** To introduce a novel 3D computerized threshold Amsler grid test, developed by Fink and Sadun, that allows for a novel characterization of the structure of visual field defects in three dimensions (see <http://www.wfbabcom5.com/wf335.htm>).

**Methods:** With one eye covered, patients are placed in front of a computer monitor displaying an Amsler grid. While focusing on a varying central fixation marker, the patients trace the areas, on a touch sensitive screen overlaying the displayed grid, that are missing from their field of vision, with their finger. The procedure is repeated with varying degrees of grid contrast. The results are recorded and later displayed as topographical contour rings, in a 3D depiction of the central hill-of-vision.

**Results:** Several clinical pilot studies have been conducted at the Doheny Eye Institute and over 200 patients have been examined so far. Conditions such as optic neuritis, anterior ischemic optic neuropathy, age-related macular degeneration, glaucoma, and ocular hypertension have been examined with the 3D visual field test. The tested visual field is limited to the central 20 to 25 degrees (depending on the computer monitor size). The physiological blind spot cannot be detected with this test due to the “fill-in phenomenon”.

**Conclusions:** The 3D computerized threshold Amsler grid test is an innovative and fast (4-5 min. per eye) visual field test. It provides several novel features, including: a) additional information through immediate 3D rather than 2D depiction of scotomas, such as location, extent, slope, depth, and shape; b) simple test-setup; c) good patient compliance. In light of results from pilot studies, the 3D visual field test appears to have the potential for the early detection and monitoring of various diseases, in particular glaucoma and macular degeneration.

## 1. Introduction

Visual field testing (perimetry) has always been an important part of an ophthalmological evaluation. In 1947 Amsler [1, 2] introduced a suprathreshold grid for evaluating the central ten degrees of the visual field. The high contrast of the standard Amsler test may fail to detect subtle field defects, such as relative scotomas.

In 1986, threshold Amsler grid testing was introduced by Wall and Sadun [3]. This test utilizes near threshold, rather than suprathreshold, visual stimuli. Contrast between the target and the background was controlled with cross-polarizing filters. With this modification it was possible to detect subtle scotomas and relative visual field defects.

Taking this a step further, Fink and Sadun computerized threshold Amsler grid testing in 2000 [4, 5]. The examination results were used to generate a three-dimensional (3D) map of the central visual field that illustrates the location, extent, slope, depth, and shape of visual field defects.

Fig. 1. The 3D computerized threshold Amsler grid test, using a computer-monitor with touch sensitive screen.

The *3D computerized threshold Amsler grid test* (see Fig. 1) is the outcome of a close collaboration over the past three years between the California Institute of Technology and the Doheny Eye Institute, Keck School of Medicine at the University of Southern California (for further details see <http://www.wfbabcom5.com/wf335.htm>).

## 2. Examination method

The 3D computerized threshold Amsler grid test uses an IBM compatible PC with a 17" monitor and touch sensitive screen (see Fig. 1). Each patient is positioned 30cm in front of the computer monitor. An eye-patch is used to cover the eye that is not being examined. Refractive correction is used with the patient's contact lenses or spectacles when necessary.

Fig. 2. Screenshot of Amsler grid at a mid grayscale level with changing central fixation marker and filled in area of scotoma.

An Amsler grid, at a preselected contrast level, is displayed on the monitor (see Fig. 2). The patient is first asked to focus on a changing stimulus at the center of the grid. In order to suppress the central Troxler effect and keep the patient's attention, the stimulus is regularly changed (changing set of characters such as letters and numbers, see Fig. 2). The patient is asked to mark the areas, on the Amsler grid, that are missing from his or her field of vision by tracing this region with their finger on the touch screen. Areas that are "missing" are defined as areas where the grid lines are missing, bent, wavy or distorted, or areas where the grid contrast differs

from the rest of the grid. The test is repeated with varying degrees of contrast. The results are recorded for later conversion into 3D format at the end of the test (see Fig. 3). The third dimension being screen contrast.

### 3. Results

Each eye, depending on the patient compliance, required a total of approximately 4 to 5 minutes to be tested.

Fig. 3. 3D display of visual field with a diagnosis of: a) optic neuropathy; b) anterior ischemic optic neuropathy; c) age-related macular degeneration; d) glaucoma; e) unimpaired central hill-of-vision; recorded by the 3D computerized threshold Amsler grid test. The x/y-axis denotes the horizontal/vertical coordinates of the visual field in degrees with (0, 0) being the center of fixation. The z-axis denotes the screen contrast expressed as a percent.

Examples from several ophthalmic disorders are depicted in Figure 3. In figure 3a the 3D plot exhibits a more scalloped-shape visual field defect in optic neuropathy, with islands of relative sensitivity. This is in contrast to a clean-cut division between vision and no vision in a case of anterior ischemic optic neuropathy (Fig. 3b) (see also [5]). This feature may have potential for differential diagnosis.

Figures 3c and 3d depict typical cases of age-related macular degeneration (see also [6]) and advanced glaucoma (see also [7]). The 3D representation of visual field defects caused by these two diseases is both intuitive (macular degeneration being a “central hole” and advanced glaucoma being a “confined mesa”) and informative: The 3D representation can be further characterized by a *slope* along the circumference of the defects. Figure 3e shows a normal central hill-of-vision at 100% contrast, for the central 20 degrees.

The 3D computerized threshold Amsler grid test has been in use since 2000 at the Doheny Eye Institute, Keck School of Medicine at the University of Southern California. Over 200 patients have been examined or screened for glaucoma, age-related macular degeneration, optic neuritis, anterior ischemic optic neuropathy, and ocular hypertension (see also [8]). In these pilot studies [5-8] the 3D test has proven to be reliable, fast, and accurate.

Subtle scotomas, hard to detect with standard automated perimetry (mainly because of limited spatial resolution, e.g., light stimulus every 6 degrees both horizontally and vertically), were repeatedly identified by the 3D test [8], suggesting a potential role as a screening instrument.

The physiological blind spot was not detected with this test because of cortical “fill-in phenomenon” for a steady grid, which is a known limitation of all Amsler grid-based tests.

Further (larger scale) clinical studies are needed to corroborate and extend the initial findings gathered with the 3D computerized threshold Amsler grid test.

#### 4. Conclusions

The 3D computerized threshold Amsler grid test is a novel approach to visual field testing that provides several additional features over conventional perimetry. The test delivers 3D rather than 2D depictions of scotomas (the z-axis reflecting contrast sensitivity) and provides insight into visual field defects, including shape and slope information about the scotoma boundaries (see Fig. 3).

This test provides characterization of the 3D structure of scotomas, thus laying the foundation for monitoring the development of scotoma profiles.

The 3D computerized threshold Amsler grid test only requires a touch sensitive screen, the test software, and an off-the-shelf computer system.

The new test is simple to use and tests are performed quickly (4-5 minutes per eye), making frequent testing feasible [9].

#### 5. References

1. Amsler M. L'examen qualitatif de la fonction maculaire. *Ophthalmologica* 1947;144:248-261.
2. Amsler M. Earliest symptoms of diseases of the macula. *Br J Ophthalmol.* 1955;37:521-537.
3. Wall M, Sadun AA. Threshold Amsler grid testing. Cross-polarizing lenses enhance yield. *Arch Ophthalmol* 1986;104(4):520-523.
4. For further information on the "3-D Computer-automated Threshold Amsler Grid Test": [http://www.jpl.nasa.gov/releases/2001/release\\_2001\\_215.html](http://www.jpl.nasa.gov/releases/2001/release_2001_215.html) and <http://www.wfbabcom5.com/wf335.htm>
5. Fink W, Hsieh AK, Sadun AA. Computer-automated 3-D visual field testing in distinguishing paracentral scotomas of Optic Neuritis vs. AION. [ARVO Abstract]. *Invest Ophthalmol Vis Sci.* 2000;41(4):S311. Abstract nr 1643.
6. Nazemi PP, Fink W, Lim JI, Sadun AA. Paracentral scotomas of age-related macular degeneration detected by means of a novel computer-automated 3-D visual field test. [ARVO Abstract] *Invest Ophthalmol Vis Sci.* 2001. Abstract nr 3799.
7. Fahimi A, Sadun AA, Fink W. Computer Automated 3D Visual Field Testing of Scotomas in Glaucoma. [ARVO Abstract] *Invest Ophthalmol Vis Sci.* 2001. Abstract nr 796.
8. Nazemi PP, Fink W, Sadun AA, Minckler D, Francis B. Early detection of glaucoma by means of a novel computer-automated 3-D visual field test. Poster and Abstract, American Academy of Ophthalmology Meeting in New Orleans 2001, Scientific Poster 33, p159.
9. Fink W, Sadun AA (2001) Prospects for Autonomous Visual Field Testing on Space Missions, lecture and poster, NanoSpace 2001, Exploring Interdisciplinary Frontiers, The International Conference on Integrated Nano/Microtechnology for Space and Biomedical Applications, March 13-16, 2001, Houston, Texas.

Figure 1



Figure 2

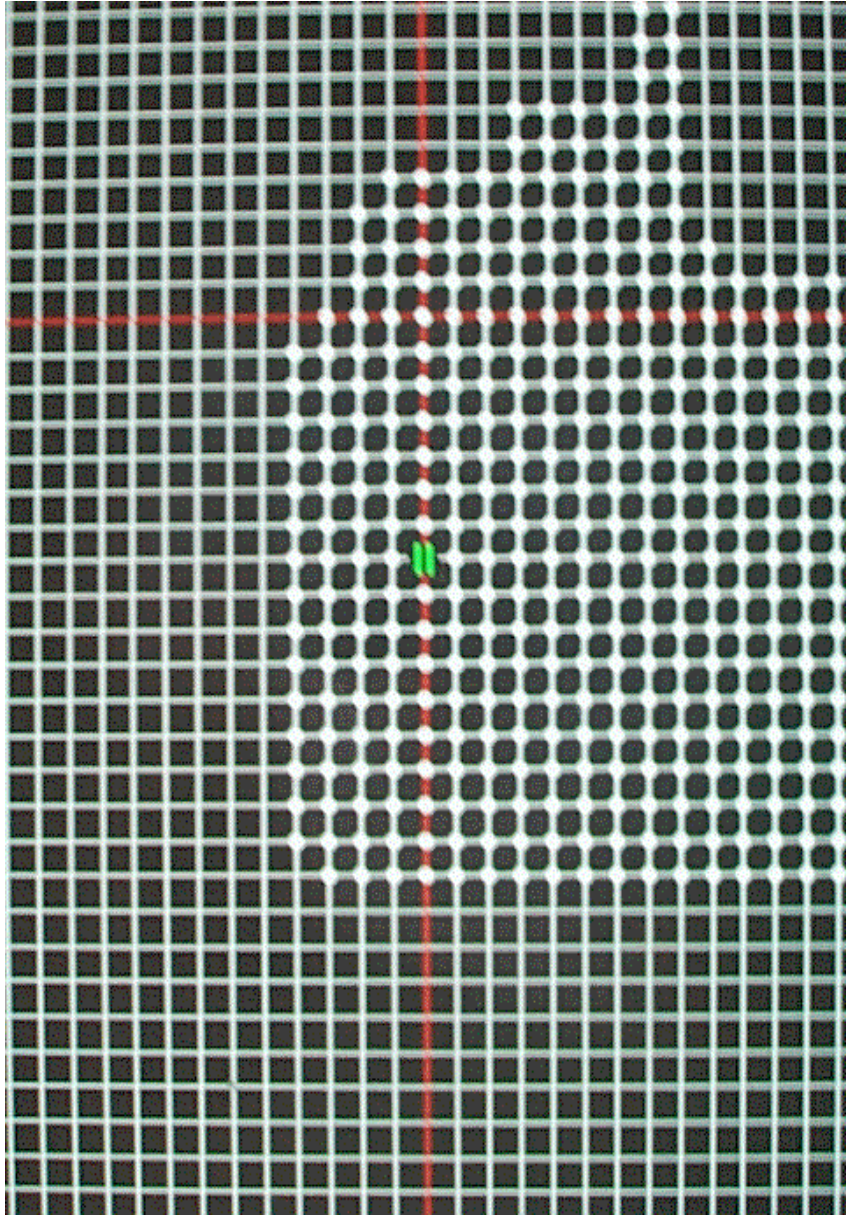


Figure 3

